

An unusual clinical presentation of acute Charcot neuroarthropathy



Author:
Neil Baker

Diabetic Charcot neuroarthropathy (CN) is an uncommon foot complication but it needs to be recognised and managed as early as possible to help prevent gross deformity. In its acute stage, it is typically characterised as being red/pink, swollen, very warm, and may have some deformity and possibly some pain. However, one of the overarching features of all CN is a loss of sensation and evidence of autonomic nerve dysfunction. The case is unusual because although the clinical features of an acute CN were present, the bedside tests commonly used for determining sensory neuropathy were absent. When further laboratory neurological function tests were performed, small and large fibre neuropathy was evident. This highlights the need for clinical vigilance when diagnosing acute CN.

Diabetic Charcot neuroarthropathy (CN) is uncommon and has a reported prevalence between 0.08% and 13% but there are no definitive epidemiological studies on Charcot foot (Frykberg and Belczyk, 2008; Rogers et al, 2016). It is a condition affecting the bones, joints and soft tissues of the foot and ankle. It is an acute localised protracted inflammatory condition resulting from the interaction of several component factors (diabetes, polyneuropathy, trauma and metabolic abnormalities of bone) which, in turn, may lead to varying degrees and patterns of bone destruction, subluxation, dislocation and deformity.

Its pathogenesis is not fully understood but peripheral sensory and sympathetic neuropathy are considered to be predisposing factors (Charcot, 1883; Eichenholtz, 1966; Johnson, 1967; Cofield et al, 1983). There have not been any reported cases of CN occurring in people with diabetes who do not have peripheral neuropathy (Rogers et al, 2011). Although not widely accepted (Stevens et al, 1992; Young et al, 1995), it has been proposed that CN patients have a wide range of sensory nerve fibre damage. However, three papers have shown that acute CN patients have C fibre mediated vasodilatory responses, in contrast with non-CN neuropathic patients (Shapiro

et al, 1998; Veves et al, 1998; Baker et al, 2007), thus demonstrating a different pattern of nerve dysfunction.

Nonetheless, due to the presence of significant peripheral sensory neuropathy, a history of accidental or perceived trauma is often unreliable (Henderson, 1905; Cofield et al 1983; Armstrong et al, 1997). The classically accepted clinical presentation of an acute CN is a red/pink/dark (depending on skin colour), swollen, warm/hot foot with mild to moderate pain, if any at all (Eichenholtz, 1966; Cofield et al, 1983; Armstrong et al, 1997; Caputo, 1998).

This clinical presentation closely resembles that of infection with cellulitis, deep vein thrombosis, or even acute gout, thus it is possible to initially misdiagnose acute CN for any of the former. The temperature difference between the affected and contralateral limb can differ by several degrees, not uncommonly by 4–7°C (Armstrong et al, 1997; McGill et al 2004). This difference in skin temperature is used as a marker of resolving of the acute phase, thus when the skin temperatures of the two limbs are $\leq 1^{\circ}\text{C}$, immobilisation of the affected limb can be gradually be removed (Rogers et al, 2011; Snyder et al, 2014).

Another clinical feature is the presence of very good and possibly exaggerated arterial flow. Characteristically, the pedal pulses when

Neil Baker is Consultant Diabetes Podiatrist, 60 Degree Vascular and Diabetic Foot Clinic, Kuwait

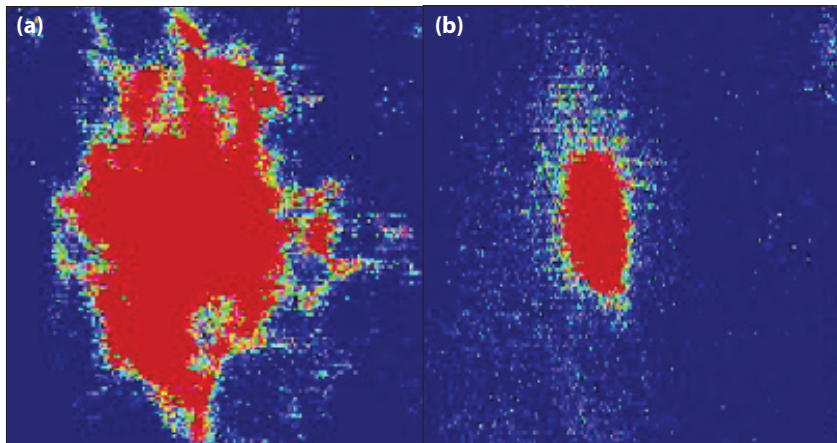
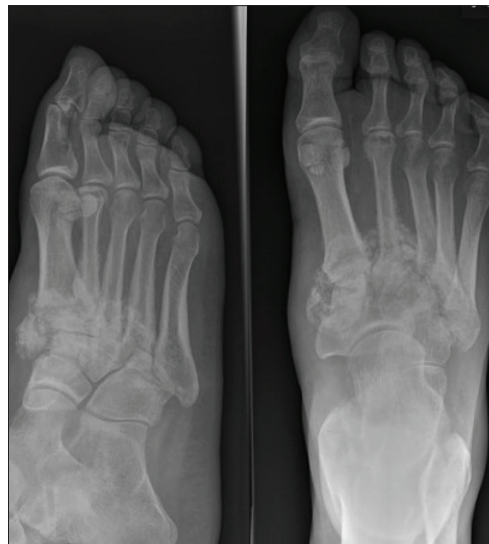

Figure 1. Laser Doppler image of skin response to heating, showing (a) Normal flare and hyperaemic response to skin heating 44°C (b) Patient is hyperaemic but no flare response to skin heating 44°C.

Figure 2. X-ray examination showing acute CN in the patients mid-foot.



palpated are very strong and often 'bounding'. Ankle pressures are frequently abnormally high, demonstrating the presence of medial wall calcification, which is a common feature of CV (Sharma et al, 2010).

In the early onset of CN, X-ray examination may appear normal but later, bony destruction becomes evident and the bones have a 'fluffy' appearance. The most frequent site for diabetic CN is the mid-foot area but it can occur in the ankle, rear or forefoot. In those with foot deformity, approximately 60% are in the tarsometatarsal joints (medial joints affected more than lateral), 30% metatarsophalangeal joints and 10% have ankle disease (Snyder et al, 2014).

The case

A very unique clinical presentation is described here, focusing on an acute CN. To date, no other similar cases have

been reported in the literature to the author's knowledge.

A 34-year-old man who has a 29-year history of type 1 diabetes was referred to a specialist diabetic foot clinic in a rural district general hospital in the UK. His general physician referred the patient with a suspected right foot infection, which had not responded to several courses of antibiotics. The patient had a history of poor glycaemic control managed by short-acting insulin three times a day but with repeated HbA_{1c} of 10% or more. He had a consistent history of non-attendance to the diabetes outpatient clinic. He had proliferative retinopathy bilaterally treated by photocoagulation 10 years previously, he also had a history of moderately increased albuminuria but no other medical history of note. On examination:

- He had a red, hot, swollen right foot, which had been present for 6 weeks
- There was no history of trauma and he described his foot as 'uncomfortable'
- There were no open wounds or history of skin trauma/breaks
- There was no tinea pedis or any other obvious clinically detectable foot complications
- All pedal pulses were very readily palpable and the patient's brachial systolic blood pressure was 138 mmHg. His pedal arteries were incompressible with ankle systolic pressures of >200 mmHg thus highly suggestive of medial wall calcification
- His neurological status was tested clinically using a 10g monofilament applied to the apex of his first, third and fifth toes, and corresponding plantar aspect of his metatarsal heads. He was able to detect light touch sensation from the 10g monofilament at all sites bilaterally
- His vibration perception thresholds were detected using a Neurothesiometer™ (Horwell medical) on the apex of both first toes. A mean of three values was recorded, with these being 14 volts (right), 12 volts (left). Thus, he had no loss of protective sensation (10g) and vibration perception thresholds within the normal range (<25volts)
- Skin temperature was recorded with a calibrated infra-red skin thermometer demonstrating a significantly hotter right foot: left foot: 30.9–31°C, right foot: 34.7–36°C
- The patient had a normal core temperature of 36.5°C with no history of systemic infection: fever rigors or sweating, and no abnormally high (for him) blood sugars.

A clinical diagnosis of acute CN was proposed,

despite the apparent intact neurological status and a plain X-ray of the right foot was ordered. The clinical findings were corroborated by a second experienced clinician who repeated the tests.

The X-ray showed destructive changes in the midfoot, consistent with acute CN. In light of this, further neurological laboratory tests were undertaken. Nerve conduction studies showed reduced large nerve fibre velocity, while a quantitative sensory test using CASE IV™ (WR Medical Electronics) showed small fibre dysfunction with hot and cold pain scores significantly reduced. Furthermore, the C fibre nerve function was tested heating the skin to 44°C and measuring the nerve mediated hyperaemic response using a scanning laser doppler imager (Baker et al, 2007). This laboratory test showed intact hyperaemia but absent flare response to heating [Figure 1].

The patient was treated for acute CN and over a 6-month period, a total of seven total contact casts were applied. The first was for 1 week, then after 2 weeks and monthly thereafter, at which stage his CN had become quiescent. Serial X-rays were taken monthly at every total contact cast change, thus overall six X-rays were taken. Subsequently, he was provided with bespoke footwear and orthoses to prevent ulceration over the planter rocker sole deformity.

To date, no other cases like this have been reported in the literature, in whom the diagnosis of CN may have been dismissed due to normal responses to clinical neuropathy screening tools. However, this case reinforces the need to be vigilant for acute CN in patients presenting with a sudden onset, red, hot, swollen intact foot, especially in the presence of easily palpable foot pulses and high ankle pressures. X-ray examination, if normal, should be repeated but an MRI should be considered together with, where possible, laboratory nerve assessment testing.

WME

References

Armstrong DG, Todd WF, Lavery LA et al (1997) The natural history of acute Charcot's arthropathy in a diabetic foot specialty clinic. *Diabet Med* 14(5): 357–63

- Baker N, Green A, Krishnan S, Rayman G (2007) Microvascular and C-fiber function in diabetic Charcot neuroarthropathy and diabetic peripheral neuropathy. *Diabetes Care* 30(12): 3077–9
- Caputo GM, Ulbrecht J, Cavanagh PR, Juliano P (1998) The Charcot foot in diabetes: six key points. *Am Fam Physician* 57(11): 2705–10
- Charcot J-M, Fere C (1883) Affections osseuses et articulaires du pied chez les tabétiques (Pied tabétique). *Archives de Neurologie* 6: 305–19 [in French]
- Cofield RH, Morrison MJ, Beabout JW (1983) Diabetic neuroarthropathy in the foot: patient characteristics and patterns of radiographic change. *Foot Ankle* 4(1): 15–22
- Eichenholtz SN (1966) *Charcot Joints*. Springfield, IL: Charles C. Thomas
- Frykberg RG, Belczyk R (2008) Epidemiology of the Charcot foot. *Clin Podiatr Med Surg* 25(1): 17–28
- Henderson VE (1905) Joint affections in tabes dorsalis. *J Pathol* 10: 211–64
- Johnson JT (1967) Neuropathic fractures and joint injuries. Pathogenesis and rationale of prevention and treatment. *J Bone Joint Surg Am* 49(1): 1–30
- McGill M, Molyneaux L, Bolton T et al (2000) Response of Charcot's arthropathy to contact casting: assessment by quantitative techniques. *Diabetologia* 43(4): 481–4
- Rogers LC, Frykberg RG, Armstrong DG et al (2011) The Charcot Foot in Diabetes. *Diabetes Care* 34(9): 2123–9
- Rogers LC, Frykberg RG, Sanders LJ (2016) The diabetic Charcot foot: recognition, evaluation and management. In: Armstrong DG, Lavery LA (eds.) *Clinical Care of the Diabetic Foot* (3rd ed). American Diabetes Association: Virginia pp99
- Shapiro SA, Stansberry KB, Hill MA et al (1998) Normal blood flow response and vasomotion in the diabetic Charcot foot. *J Diabetes Complications* 12(3): 147–53
- Sharma A, Scammell BE, Fairbairn KJ et al (2010) Prevalence of calcification in the pedal arteries in diabetes complicated by foot disease. *Diabetes Care* 33(5): e66
- Snyder RJ, Frykberg RG, Rogers LC et al (2014) The management of diabetic foot ulcers through optimal off-loading building consensus guidelines and practical recommendations to improve outcomes. *J Am Podiatr Med Assoc* 104(6): 555–67
- Stevens MJ, Edmonds ME, Foster AV, Watkins PJ (1992) Selective neuropathy and preserved vascular responses in the diabetic Charcot foot. *Diabetologia* 35(2): 148–54
- Veves A, Akbari CM, Primavera J et al (1998) Endothelial dysfunction and the expression of endothelial nitric oxide synthetase in diabetic neuropathy, vascular disease, and foot ulceration. *Diabetes* 47(3): 457–63
- Young MJ, Marshall A, Adams JE (1995) Osteopenia, neurological dysfunction, and the development of Charcot neuroarthropathy. *Diabetes Care* 18(1): 34–8