



# QUICK GUIDE

*Managing*

## PERISTOMAL SKIN COMPLICATIONS



**Wounds**  
INTERNATIONAL

## HOLISTIC ASSESSMENT




- Conduct a full holistic assessment of the patient—including full medical history, diagnosis requiring stoma, mobility status, comorbidities, history of skin problems and any interventions/treatments already undertaken.<sup>6</sup>
- Perform a visual inspection and physical examination of the stoma and peristomal skin—including general appearance, skin integrity, presence and distribution of hair; compare the peristomal skin with adjacent abdominal skin, checking for any changes.<sup>6</sup>
- Assess the patient's current appliance and any effect this has on the skin. Consider switching to another appliance if necessary, and use appropriate accessories to protect the skin.<sup>6</sup>
- Educate the patient on hygiene, and pouch application and removal. Provide information and support on self-care and ongoing management.<sup>6</sup>



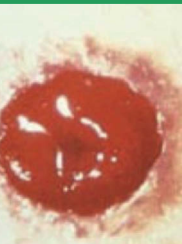### Skin care tips

- ✓ Clean the skin with a pH-balanced product (or in some cases water alone may be used).<sup>3</sup> Do not use emollient or oil-based products, as well as those that may dry the skin. Avoid chemicals that may cause irritation.<sup>6</sup>
- ✓ Maintain dry skin in order to reduce the risk of candidiasis. Dry skin is also essential to obtaining a good adhesive seal. After bathing with the pouch on, dry the skin and the pouching system carefully.<sup>3</sup>
- ✓ Protect the skin by using nontraumatic adhesives and cleansing the skin carefully. Remove adhesives gently in order to avoid trauma/skin stripping. Consider using a skin sealant to prevent trauma in patients with sensitive skin.<sup>3</sup>

# Examples of common peristomal skin complications

	Dermatitis	Pressure damage	
Condition			
	<p><b>Dermatitis</b>, caused either by a reaction to any component of the appliance (hypersensitivity reaction), or by contact with the stoma effluents (moisture-associated skin damage)<sup>4,5</sup></p>	<p><b>Pressure damage</b>, caused by tightness or excessive pressure of belt or any appliance that is too tight/rigid<sup>3,5</sup></p>	<p><b>Folliculitis</b>, caused by bacterial infection of the hair follicles, often by stoma effluents or by mechanical irritation from the appliance<sup>3</sup></p>
Symptoms	<p>Redness/rash, swelling, tenderness, heat, effusion, pain/itching<sup>4,5</sup></p>	<p>Erythema that does not resolve within 1-2 minutes of removing a pouching system<sup>5</sup></p>	<p>Lesions that are often itchy, sometimes painful, and may be accompanied by erythema and superficial pustules<sup>3</sup></p>
Management	<p>Avoid substances that cause allergic reaction,<sup>3</sup> and consider using an adhesive remover. Do not use products/chemicals unless there is a specific indication for the individual patient.<sup>3</sup> Check the appliance fits correctly and adapt if necessary.<sup>3</sup> Consider using a barrier product such as Askina® Barrier Film.</p>	<p>Assess the skin rigorously for pressure/skin damage.<sup>3</sup> Discontinue the use of a belt where possible, or loosen when in use.<sup>3</sup> If pressure damage occurs, consider management with thin hydrocolloid dressings (e.g. Askina® Biofilm transparent or Askina® ThinSite).<sup>3</sup></p>	<p>Recommend gentle skin care, such as shaving, and avoid harsh products. Do not use products unless there is a specific indication for the individual patient.<sup>3</sup> Consider using a barrier product such as Askina® Barrier Film.</p>

## Folliculitis



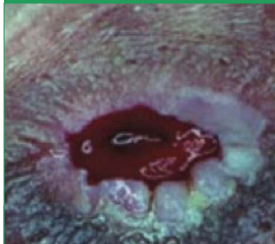**Folliculitis**, usually caused by staphylococcal infection, is a common resulting complication from removing hair from the skin around the pouch.<sup>4,5</sup>

It originates from the hair follicle, some are pustular and with an erythematous periphery, tends to be superficial.<sup>4,5</sup>

Recommend a gentle cleansing procedure that is performed more than once a week.<sup>3</sup>

Consider antibacterial products.<sup>3</sup>  
Consider using a barrier product (e.g. Askina® Barrier Film and/or Superfiller).<sup>3</sup>

## Hypertrophy/papillary changes

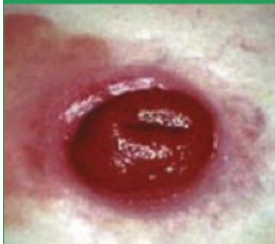

**Hypertrophy/papillary changes**, which are caused by chronic exposure of the skin to urine<sup>5</sup>

When the skin is exposed to alkaline urine, crystalline crusts are often formed on the skin surface - this may lead to wart-like hypertrophy and a subsequent inflammatory response<sup>5</sup>

Consider use of seal or similar products.<sup>3,5</sup>  
Urine may be acidified by the patient ingesting cranberry juice or vitamin C.<sup>3,5</sup>  
Consider a barrier product (e.g. Askina® Barrier Film and/or Superfiller).<sup>3</sup>

## Yeast infection (candidiasis)



**Yeast infection (candidiasis)**, which may be caused by leakage, excessive sweating of the skin, antibiotic therapy, or broken skin<sup>4,5</sup>

Initially presents as a pustule, progresses to erythemic confluent plaque with satellite lesions; burning, itching<sup>4,5</sup>

Treat with antifungal powder at each pouch change until resolved.<sup>3</sup>  
Educate patient in drying technique and how to avoid a moist environment.<sup>3</sup>  
Consider a skin sealant or protective skin barrier product (e.g. Askina® Barrier Film and/or Superfiller).<sup>3</sup>

# Understanding peristomal skin complications

Unlike wounds, where the ultimate treatment goal is healing, stomas are a breach of the skin that are designed to stay open in order to drain the stoma effluents. Complications to the peristomal skin are common and require specific management.<sup>1</sup>

Complications related to the stoma may be surgical or dermatological. Dermatological complications are common, causing a wide range of symptoms and occurring in 45% of patients,<sup>1</sup> and have been shown to have a significant adverse effect on the patient's quality of life.<sup>2</sup> Peristomal skin problems account for more than one in three visits to ostomy nurses.<sup>2</sup>

Therefore the surrounding skin requires scrupulous care to maintain its health and avoid dermatological complications. Healthy skin around the stoma is essential to ensure good adhesion, without which the risk of leaking and further skin damage is increased and creates a vicious circle of skin damage and pouch leakage.<sup>3</sup>

Preventative action is the most important element of care—the best way to manage peristomal skin conditions is to prevent them in the first place.<sup>3</sup> Effect preventative strategies and patient education are vital. Identifying risk factors can help to optimise care. Assessment is crucial—it is important to conduct a targeted visual inspection as well as taking both a holistic and focused patient history.<sup>3,4</sup>

# PERISTOMAL SKIN ASSESSMENT TOOLS

Several assessment tools for peristomal skin conditions are available. These assessment tools may help facilitate documentation, tracking the patient's condition and assessing outcomes.<sup>8</sup> Two of these assessment tools are described below.



## SACS Instrument (Studio Alterazioni Cutanee Stomali or Study on Peristomal Skin Lesions)<sup>7</sup>

Scoring system based on two elements:

- Lesion description: severity and depth of tissue damage (L). The type of lesion is then subcategorised into four types: hyperemic; erosive; ulcerative (with or without nonviable tissue); proliferative.
- Topography: location of the wound around the stoma (T).



## DET score system (Discoloration, Erosion, Tissue overgrowth)<sup>8</sup>

Instrument for assessment of the extent and severity of peristomal skin change, in terms of:

- D - Discoloration
- E - Erosion
- T - Tissue overgrowth.

### References

1. Herlufsen P et al (2006) Study of peristomal skin disorders in patients with permanent stomas. *British Journal of Nursing* 15(16):854-62
2. Jemek GBE, Nybaek H (2008) Peristomal skin problems account for more than one in three visits to ostomy nurses. *British Journal of Dermatology* 159:1207-14
3. Rolstad BS, Erwin-Toth P (2004) Peristomal skin complications: prevention and management. *Ostomy Wound Management* 50(9):68-77
4. Nybaek H, Jemek GBE (2010) Skin problems in stoma patients. *JEADV* 24:249-57
5. Woo KY, Sibbald RG, Ayello EA et al (2009) Peristomal skin complications and management. *Adv Skin Wound Care* 22:522-32
6. Gray M, Colwell JC, Doughty D et al (2013) Peristomal moisture-associated skin damage in adults with fecal ostomies. *J Wound Ostomy Continence Nurs* 40(4):389-99
7. Boslo G, Pisani F, Lucibello L et al (2007) A proposal for classifying peristomal skin disorders: results of a multicenter observational study. *Ostomy Wound Management* 53(9):38-43
8. Jemek GB, Martins L, Claessens I (2011) Assessing peristomal skin changes in ostomy patients: Validation of the Ostomy Skin Tool. *British Journal of Dermatology* 164:330-5