

WORLD UNION
OF
WOUND HEALING SOCIETIES



WORLD UNION OF WOUND HEALING SOCIETIES
POSITION DOCUMENT

UNDERSTANDING HIDRADENITIS SUPPURATIVA

Managing and treating HS

Managing HS: approaches to wounds in pre-surgical and post-surgical phases

Addressing the impact of HS on quality of life and daily activities



PUBLISHER

Clare Bates

MANAGING DIRECTOR

Rob Yates



www.wuwhs.net

How to cite this document

World Union of Wound
Healing Societies (WUWHS),
Florence Congress, Position
Document. *Understanding
hidradenitis suppurativa*. Wounds
International, 2016

Produced by
Wounds International — a division of Omnia-Med Ltd
1.01 Cargo Works, 1-2 Hatfields, London, SE1 9PG

All rights reserved ©2016. No reproduction, copy or transmission of this publication may be made without written permission.

No paragraph of this publication may be reproduced, copied or transmitted save with written permission or in accordance with the provisions of the Copyright, Designs and Patents Act 1988 or under the terms of any licence permitting limited copying issued by the Copyright Licensing Agency, 90 Tottenham Court Road, London, W1P 0LP

Hidradenitis suppurativa is a chronic, disabling condition that often relentlessly progresses. Occurring in often otherwise healthy adolescents and adults, this rare disease manifests in painful lesions that may cause hypertrophic scars and immobility.

Historically, it is often underdiagnosed because patients are embarrassed to seek help for the condition, which significantly impacts on daily life, physically, emotionally and psychologically.

Diagnosis of the disease is primarily clinical with no pathognomonic tests currently available. Many uncertainties remain following diagnosis, including the course of the disease, the number of flare-ups that may occur and expectation of a life free of symptoms.

Medical management is recommended in the early stages. Other interventions, including laser treatment, offer an alternative to surgery in mild-to-severe cases with surgery deemed as the most efficacious option in chronic and recurrent stages of HS.

Surgical treatment remains the most common and accepted modality for HS, because many traditional, non-surgical interventions do not result in a lasting cure. Several surgical treatment methods co-exist and are recommended with the type of surgery and margins selected based on severity of the disease and body region affected.

This Position Document looks at the management and care of HS across the treatment spectrum. Paper 1 looks at the efficacy of currently available treatment options and details the medical therapies available for treatment of HS, including topical therapies and systemic treatments such as antibiotics, sulphones, retinoids, hormones and immunosuppressants to laser treatment and radical surgery.

Paper 2 takes a deep dive into the pre- and post-surgical landscape of HS with an in-depth look at conventional surgery, CO₂ laser therapy and experimental therapies, and their varying success rates.

Paper 3 explores the impact the condition has on patients' quality of life with an in-depth look at the use of quality of life indexes as part of a care management plan. It also seeks to address some of the treatment and dressing inequalities that exist in managing and treating the condition, and how the social and economic impact of HS could and should be addressed.

Authors

Valentina Dini, MD PhD, Assistant Professor, Department of Dermatology, University of Pisa, Italy
Afsaneh Alavi, Assistant Professor of Medicine (Dermatology), University of Toronto, Ontario, Canada

Thomas Wild, Surgeon, Wound Center Dessau-Rosslau Department of Dermatology, Dessau Municipal Hospital, Germany

Reviewers

Robert Kirsner, Department of Dermatology and Cutaneous Surgery, University of Miami Miller School of Medicine, Miami, Florida, USA

Peter Vowden, Visiting Honorary Professor of Wound Healing Research, University of Bradford and Honorary Consultant Vascular Surgeon, Bradford Teaching Hospitals NHS Foundation Trust, Bradford, UK

Managing and treating HS

Hidradenitis suppurativa (HS) is a chronic, inflammatory, recurring dermatosis of the hair follicle. Sometimes referred to as apocrinitis, *acne inversa* and *pyoderma fistulans significa*, it presents, after puberty, with painful, deep-seated inflamed lesions in the apocrine gland-bearing areas of the body such as axillary, inguinal, genitofemoral, gluteal, perineal and inframammary region (Box 1)^[1].

Active typical lesions, such as nodules and abscesses can cause embarrassment; residual scarring may be disfiguring and may result in dermal contractures and lymphoedema, causing restricted limb mobility, painful skin tension and psychological distress, with a major impact in the life of the patients. In addition, HS can also appear at uncommon sites including areola of the breast, the submammary fold, the periumbilical skin, the scalp, the zygomatic and malar areas of the face, the buttocks, the thighs and the popliteal fossa^[2].

EPIDEMIOLOGY

Prevalence is reported to be around 1% in Europe^[3] and around 0.05% in US^[4], but there is an important variability in prevalence or incidence estimations in different studies and the actual frequency of HS still remains unknown. Women are almost 3 times more affected than men, and the prevalence is highest in people aged 18 to 44 years^[4]. HS occurs in all races but its incidence is higher in African and Afro-Caribbean populations than in Caucasians^[5].

AETIOPATHOGENESIS

The hair follicular unit has a key role in the disease development, Yu and Cook (1990)^[6] demonstrated that keratin plugging of follicles is an early phenomenon and the inflammation of apocrine glands is a secondary feature^[6].

The connection between disease severity and BMI, as well as smoking has been reported in HS patients^[5]. A majority of patients who reported remission had stopped smoking or had never smoked. It has been proposed that alkaloids in cigarettes are able to promote the *Staphylococcus aureus* proliferation and thus change microbiome^[7]. This

Box 1: Clinical manifestations and diagnosis

HS usually involves axillary, inguinal, genitofemoral, gluteal, perineal and inframammary areas, but can also involve other anatomical sites, such as peristomal hidradenitis, described by Fleischer in 1996. A recent history of recurrent lesions — at least 2 in the past 6 months — in typical HS areas, is the primary diagnostic criterion of HS. A positive family history of HS and the presence of normal skin microbiota can be considered positive support for diagnosis^[1].

Typical HS lesions are mainly

- deep-seated, inflamed or non-inflamed nodules
- chronic painful abscesses
- fistulas
- cysts
- draining sinus tracts
- open tombstone comedones
- scars^[1]

Valentina Dini, MD, PhD
Assistant Professor,
Department of Dermatology,
University of Pisa, Italy

“Therapeutic choice in HS patients is based on the severity of the disease, type of lesions, extension of involved area and resistance to previous treatments”

possible mechanism is in contrast with the low prevalence of *S. aureus* in HS lesions. Another possible cause is the secretion of nicotine in sweat that can lead to an epidermal hyperplasia, release of TNF α , a follicular occlusion and a decrease in macrophage and lymphocyte activity^[8].

Obesity is an important risk factor, the proposed mechanisms of action include local factors such as warmth and humidity in the skin folds in these patients. A positive correlation between the body mass index (BMI) and the severity of disease has been shown. A 15% weight reduction in patients with BMI>30 has been shown to improve HS^[9].

Genetic factors, such as heterozygous mutations in subunits of the gamma-secretase, are involved in the pathogenesis of the disease in some patients^[10].

Bacteria found in HS lesions are various and are usually part of the normal skin microflora, with a central role of coagulase-negative staphylococci (CNS). These microorganisms have been considered either as contaminants or as the result of a secondary infection^[11]. The role of hormones, in particular androgens, is also relevant in some patients^[12]. In addition, patients with HS were found to have low levels of vitamin D, however this needs further investigation^[13]. In a wide study in HS patients the association with depression and anxiety have been described as statistically significant^[13].

COMORBIDITIES

HS could be associated with several concomitant and secondary diseases such as obesity, metabolic syndrome, inflammatory bowel diseases, squamous cell carcinoma, *pyoderma gangrenosum*, SAPHO Syndrome (synovitis, acne, palmar-plantar pustulosis, hyperostosis, osteitis), Beçet’s disease, spondyloarthropathy, pachyonychia congenita, Dowling-Degos disease, Keratitis Ichthyosis Deafness syndrome and Down syndrome^[3,14].

Box 2: Severity assessment

Hurley staging

HS is commonly categorised using the Hurley Staging System, which comprises 3 stages

- Stage I corresponds to isolated lesions, without sinus tracts and scars
- Stage II is characterised by one or more recurrent abscesses with cicatrization and tract formation
- Stage III is represented by interconnected tracts and multiple abscesses involving an extended area^[1].

Most patients have Stage I disease, Stage II affects about one-third of patients with about 4% of patients categorised as Stage III. This grading system is useful in classifying HS patients and helping to select the most appropriate treatment for each patient.

Sartorius score

In 2003, Sartorius et al^[15] created a highly detailed score system based predominantly on the number and type of lesions, anatomical region involved and presence of healthy skin. This system, which was later modified, is more laborious than Hurley’s and it still has technical limits in measuring clinical improvement of the disease.

Physician global assessment

More recently, the Physician Global Assessment (PGA) has been successfully used as an assessment tool in clinical evaluations of patients with HS. It comprises 6 stages that accurately define the severity of the disease and it could be a good system to evaluate treatment response.

Hidradenitis Suppurativa Severity Index

Hidradenitis Suppurativa Severity Index (HSSI) analyses objective and subjective parameters and has been used to evaluate the efficacy of infliximab therapy in HS patients^[1].

MEDICAL THERAPIES FOR HS

Therapeutic choice in HS patients is based on the severity of the disease, type of lesions, extension of involved area and resistance to previous treatments. Several topical and systemic therapies have been suggested in case reports, but few randomised clinical trials have been performed^[3,16].

Topical treatments

Topical therapy can be useful to treat localised lesions in patients with Hurley Stage I or II HS.

- Clindamycin 1% was effective in a double-blinded randomised trial, especially for the treatment of superficial lesions^[17]
- Topical resorcinol 15% was shown to be effective in stage I or II HS patients due to its exfoliant properties and ability to improve lesional draining^[18]
- Intralesional injections of triamcinolone acetonide rapidly reduce inflammation in acute flare-ups and can be useful in the treatment of refractory nodules and sinus tracts^[19]
- Ketoprofen topical preparation could be efficient in the treatment of inflammatory pain, showing good skin permeability^[20]
- Botulinum toxin A (BTXA) has been successfully used in few cases, but the mechanism is still unknown^[21].

Systemic treatments**■ Antibiotics**

- The combined use of systemic rifampicin and systemic clindamycin showed good results in the treatment of inflammatory lesions in any Hurley Stage HS^[22,23]. Patients with severe refractory HS have been treated with a combination of rifampicin, moxifloxacin and metronidazole, obtaining complete remission in 16/28 patients^[24]
- Oral isoniazid was used in a small group of patients but no significant improvement was observed^[25]
- A clinical trial compared results of treatment of Stage I or II HS patients with topical clindamycin and systemic tetracycline — no significant differences were found^[26].

■ Sulphones

- Dapsone (4'4'-diaminodiphenyl sulphone) should be considered when standard therapies have failed. Improvement of HS lesions was reported in treated patients, however treatment interruption is characterised by rapid relapses^[27].

■ Retinoids

- Isotretinoin inhibits sebaceous gland activity and induces clinical improvement in acne vulgaris and may potentially prevent the occlusion of an affected pilosebaceous unit by ductal hypercornification in HS patients but it is not effective in the treatment of HS and it is not recommended in these patients^[2,3,4]
- A high daily dosage of acitretin showed good results in HS patients, with a significant rapid improvement of clinical manifestations^[28].

■ Hormones

In female patients with HS with abnormal levels of androstenedione and/or sexual hormone-binding protein, the use of anti-androgens and oestrogens can be considered as an alternative.

- Cyproterone acetate (anti-androgen) 100mg/day combined with ethinyl oestradiol showed clinical improvement of the disease, but it failed after anti-androgen dosage reduction^[29]
- Leuprolide acetate (gonadotropin-releasing hormone agonist), combined with dexamethasone, was successfully used in a severe case of HS^[30]
- Finasteride, an inhibitor of type II 5 α reductase, can be effective in recalcitrant HS male and female patients^[31]

“Most patients have Stage I disease, Stage II affects about one-third of patients with about 4% of patients categorised as Stage III”

- A case series of 20 HS patients treated with spironolactone showed the efficacy of this therapeutic option in women with HS, with relatively few side effects^[32].

■ **Immunosuppressive drugs**

- Systemic corticosteroids, such as hydrocortisone, dexamethasone and prednisolone have been prescribed as short-term and long-term therapies, however, they are not recommended for long-term use^[3]
- Cyclosporine was used with satisfying results in HS patients with long-lasting history of the condition that had not responded to standard therapies, either monotherapies or combined with corticosteroids^[33]
- Methotrexate has limited value in the treatment of HS, primary lesions showed no clinical improvement and frequency of flare-ups as unchanged after treatment^[34].

Studies have supported the use of anti-TNF α drugs, such as adalimumab, infliximab and etanercept, in the treatment of moderate to severe HS.

Adalimumab can be used ahead of a curative surgical procedure at the dose of 160mg on day 0 potentially reducing to 80mg 1 week later^[3]. In management of moderate-to-severe HS, long-term treatment with 40mg adalimumab, once weekly can result in improvements in patient-reported outcomes and pain^[22].

Infliximab can also be used ahead of a curative surgical procedure at a dose of 5mg/kg body mass and as a long-term therapy at 5mg/kg body mass in weeks 0, 2 and 6 and thereafter one dose (5mg/kg of body mass) a week for 8 weeks^[3].

A retrospective study was performed to compare 2 cohorts of 10 adult patients suffering from severe, recalcitrant HS. In 2005, 10 patients were treated with infliximab intravenous (i.v.) (3 infusions of 5 mg/kg at weeks 0, 2, and 6). In 2009, 10 other patients were treated in the same hospital with adalimumab subcutaneous (s.c) 40mg every other week. Both cohorts were followed-up for 1 year using identical evaluation methods, these included the Sartorius score, quality of life index, reduction of erythrocyte sedimentation rate (ESR) and C-reactive protein (CRP), patient and doctor global assessment, and duration of efficacy^[35].

Nineteen patients completed the study — in both groups the severity of HS had reduced. Infliximab performed better in all aspects: the average Sartorius score was reduced to 54% of baseline for infliximab and 66% of baseline for adalimumab. The study concluded that adalimumab s.c. 40mg every other week is less effective than infliximab i.v. 5mg/kg at weeks 0, 2 and 6^[35].

The use of etanercept in the treatment of HS showed only minimal evidence of clinically significant efficacy^[35].

IL 12-23 blockers, such as ustekinumab, can be considered a useful and safe treatment in II—III Hurley stage HS patients^[36]. A study to assess the safety and efficacy of ustekinumab, where patients received 3–45mg s.c. injections at 0, 1 and 4 months, showed that ustekinumab may provide a safe and effective new treatment strategy for HS in some patients. Improvement was assessed by dermatology life quality index (DLQI), visual analogue scale of pain (VAS) and physicians global assessment (PGA) at each monthly visit.

Prior to treatment, patients had moderate to severe HS (Hurley Stage II–III) with a DLQI score between 8 and 12. At 6 months, one patient showed complete remission, while a 25%–49%

improvement was seen in a second patient and no change in the third. A moderate but statistically significant relationship was observed between VAS and DLQI scores ($r = 0.75$; $P < 0.01$). Interleukin 12/23 inhibition is a potential therapeutic option for patients in which other therapies prove ineffective.

Biological drugs may provide an effective treatment strategy for severe HS patients, however recurrences often occurred after discontinuation of therapy.

■ Other therapies

Significant improvement of DLQI and average reduction in Sartorius score was observed in HS patients treated with metformin for 24 weeks, with minimal side effects^[37]. Brocard et al^[38] described a positive clinical response in all patients treated with zinc salt that can be considered a valid therapeutic alternative or an adjuvant therapy in treating HS^[38].

There is currently no sufficient clinical evidence for the use of non-steroidal anti-inflammatory drugs, opiates, colchicine and intramuscular gamma globulin in HS patients^[3].

SURGICAL THERAPIES FOR HS

There are several types of surgical treatments available for HS — choosing the most appropriate technique should be based on the severity of the disease and the anatomical sites involved.

- Simple incision and drainage of individual lesions: this may lead to partial relief but it is not recommended because of the high rate of recurrence^[39]
- Electrosurgery resulted in high cure rates in patients with Stage I-II of HS^[40]
- Skin-Tissue-sparing Excision with Electrosurgical Peeling (STEEP) is a valid technique for treatment of Hurley Stage II and III HS patients; characterised by short time healing, high patient satisfaction and cosmetically good results^[41]
- Complex surgical procedures that need resurfacing with skin grafts or flaps showed lower recurrence rates when compared with partial excisions with primary closure^[42]
- The deroofting technique is based on surgical removal of the roof of the lesion followed by wound healing. This technique maximises preservation of surrounding healthy tissue and is associated with cosmetically acceptable scars. However, recurrences may occur^[43].

When a patient is unable to undergo the traditional medical or surgical treatments cryoinsufflation may be an alternative treatment^[44].

LASER TREATMENT FOR HS

Carbon dioxide (CO₂) laser treatment provides a rapid and incisive result and makes a significant impact on quality of life. This treatment is suitable for patients with mild-to-severe disease and can be performed under local or general anaesthesia. It is associated with both primary closure and healing by secondary intention. Micro-fractionated 10 600nm CO₂ laser promotes physical scar remodelling, improves skin elasticity and reduces erythema^[45].

CO₂ laser treatment, followed by second-intention healing, allows good haemostasis and it is related to minimal complications, with linear and flat residual scars^[46]. The results of the procedure with the CO₂ laser are satisfying and are characterised by less scarring and pain compared with traditional surgical therapy and with untreated lesions^[47]. Recurrences can develop in the treated area and new lesions can appear on the skin around the treated site^[48].

Considering the role of the hair follicle unit in the pathogenesis of HS, selective photothermolysis of the follicular unit using Nd:YAG hair removal laser has been performed, with statistically significant improvement in HS severity^[49]. Patients with HS treated with 800nm and 1450nm diode laser showed partial improvement, the treatment with 1450nm diode laser is associated with a reduction of sweating^[50,51].

Laser therapy can be an alternative to conventional surgery that allows an efficient treatment of both HS active lesions and residual scars.

PHOTODYNAMIC THERAPY (PDT)

PDT utilises a molecular energy exchange between visible light and a photosensitive drug, such as 5-aminolevulinic acid (PDT-ALA) or its methyl ester (PDT-MAL), resulting in the production of reactive oxygen species (ROS). It induces selective cell necrosis, breaks up biofilms and shows immunomodulatory effects. It is possible to use PDT as an adjuvant therapy in HS patients and it should be used with MAL or intralesional ALA, but it is not a first-line treatment^[52,53].

CONCLUSION

HS is a chronic and stubborn disease centred on inflammation of the large specialised sweat glands (apocrine glands) that are found mainly in the armpits and groin. These areas show a distinctive mixture of boil-like lumps, areas leaking pus and scarring.

There are a number of medical treatments, including topical and systemic interventions, and surgical treatments from simple incision to complex surgical procedures and laser treatment that have proved effective at different stages of the condition, which vary in terms of efficacy from medical to surgical interventions and laser therapies.

REFERENCES

1. Zouboulis CC, del Marmol V, Mrowietz U, Prens E, Tzellos T, Jemec GBE. Hidradenitis suppurativa/acne inversa: Criteria for diagnosis, severity assessment, classification and disease evaluation. *Dermatology* 2015; 231:184-90.
 2. Plewig G, Steger M. Acne inversa (alias acne triad, acne tetrad or hidradenitis suppurativa). In *Acne and Related Disorders: International Symposium Proceedings*. Marks R, Plewig G (eds). Taylor & Francis: London 1990; pp345-57.
 3. Zouboulis CC, Desai N, Emtestam L et al. European S1 guideline for the treatment of hidradenitis suppurativa/acne inversa. *J Eur Acad Dermatol Venereol* 2015; 29(4): 619-44.
 4. Revuz JE, Canoui-Poitrine F, Wolkenstein P et al. Prevalence and factors associated with hidradenitis suppurativa: results from two case-control studies. *J Am Acad Dermatol* 2008; 59: 596-601.
 5. Cosmatos I, Matcho A, Weinstein R et al. Analysis of patient claims data to determine the prevalence of hidradenitis suppurativa in the United States. *J Am Acad Dermatol* 2013; 68(3):412-9.
 6. Yu CC, Cook MG. Hidradenitis suppurativa: a disease of follicular epithelium, rather than apocrine glands. *Br J Dermatol* 1990; 122(6):763-9.
 7. Sartorius K, Emtestam L, Jemec GB, Lapins J. Objective scoring of hidradenitis suppurativa reflecting the role of tobacco smoking and obesity. *Br J Dermatol* 2009; 161(4):831-9.
 8. Kurzen H, Kurokawa J, Jemec JBE et al. What causes hidrosadenitis suppurativa? *Exp Dermatol* 2008; 17:455-6.
- Servetiy
11. Jemec GB, Faber M, Gutschik E, Wendelboe P. The bacteriology of hidradenitis suppurativa. *Dermatology* 1996;193(3):203-6.
 12. Mortimer PS, Dawber RP, Gales MA, Moore RA. Mediation of hidradenitis suppurativa by androgens. *Br Med J (Clin Res Ed)* 1986; 292(6515):245-8.
 13. Shavit E, Dreier J, Freud T, et al. Psychiatric comorbidities in 3207 patients with hidradenitis suppurativa. *J Eur Acad Dermatol Venereol* 2015; 29(2):371-6.
 14. Fimmel S, Zouboulis CC. Comorbidities of hidradenitis suppurativa (acne inversa). *Dermatoendocrinol* 2010;2:9-16.
 15. Sartorius K, Lapins J, Emtestam L, Jemec GB. Suggestions for uniform outcome variables when reporting treatment effects in hidradenitis suppurativa. *British journal of dermatology* 2003 Jul 1; 149(1):211-3.
 16. Gulliver W, Zouboulis CC, Prens E, Jemec GB, Tzellos T. Evidence-based approach to the treatment of hidradenitis suppurativa/acne inversa, based on the European guidelines for hidradenitis suppurativa. *Rev Endocr Metab Disord* 2016;[Epub ahead of print]
 17. Clemmensen OJ. Topical treatment of hidradenitis suppurativa with clindamycin. *Int J Dermatol* 1983; 22(5):325-8.
 18. Boer J, Jemec GB. Resorcinol peels as a possible self-treatment of painful nodules in hidradenitis suppurativa. *Clin Exp Dermatol* 2010; 35(1):36-40.
 19. Jemec GBE, Revuz J, Leyden JJ, eds. *Hidradenitis suppurativa*. Berlin: Springer Verlag 2006.
 20. Komatsu T, Sakurada T. Comparison of the efficacy and skin permeability of topical NSAID preparations used in Europe. *Eur J Pharm Sci* 2012; 47(5):890-5.
 21. Khoo AB, Burova EP. Hidradenitis suppurativa treated with Clostridium botulinum toxin A. *Clin Exp Dermatol* 2014; 39(6):749-50.
 22. Gener G, Canoui-Poitrine F, Revuz JE, et al. Combination therapy with clindamycin and rifampicin for hidradenitis suppurativa: a series of 116 consecutive patients. *Dermatology* 2009; 219(2):148-54.
 23. Mendonça CO, Griffiths CE. Clindamycin and rifampicin combination therapy for hidradenitis suppurativa. *Br J Dermatol* 2006; 154(5):977-8.
 24. Join-Lambert O, Coignard H, Jais JP et al. Efficacy of rifampin-moxifloxacin-metronidazole combination therapy in hidradenitis suppurativa. *Dermatology* 2011; 222:49-58.
 25. Miller IM, Dufour DN, Jemec GB. Treatment of hidradenitis suppurativa: is oral isoniazid an option? *J Dermatolog Treat* 2012; 23(2):128-30.
 26. Jemec GB, Wendelboe P. Topical clindamycin versus systemic tetracycline in the treatment of hidradenitis suppurativa. *J Am Acad Dermatol* 1998; 39:971-74.
 27. Kaur MR, Lewis HM. Hidradenitis suppurativa treated with dapsone: A case series of five patients. *J Dermatolog Treat* 2006; 17(4):211-3.
 28. Matusiak L, Bieniek A, Szepletowski JC. Acitretin treatment for hidradenitis suppurativa: a prospective series of 17 patients. *Br J Dermatol* 2014; 171(1):170-4.
 29. Sawers RS, Randall VA, Ebling FJ. Control of hidradenitis suppurativa in women using combined antiandrogen (cyproterone acetate) and oestrogen therapy. *Br J Dermatol* 1986; 115:269-74.
 30. Camisa C, Sexton C, Friedman C. Treatment of hidradenitis suppurativa with combination hypothalamic-pituitary-ovarian and adrenal suppression. A case report. *J Reprod Med* 1989; 34:543-46.
 31. Joseph MA, Jayaseelan E, Ganapathi B, Stephen J. Hidradenitis suppurativa treated with finasteride. *J Dermatolog Treat* 2005; 16(2):75-8.
 32. Lee A, Fischer G. A case series of 20 women with hidradenitis suppurativa treated with spironolactone. *Australas J Dermatol* 2015. [Epub ahead of print]
 33. Rose RF, Goodfield MJ, Clark SM. Treatment of recalcitrant hidradenitis suppurativa with oral ciclosporin. *Clin Exp Dermatol* 2006; 31(1):154-5.
 34. Jemec GB. Methotrexate is of limited value in the treatment of hidradenitis suppurativa. *Clin Exp Dermatol* 2002; 27(6):528-9.
 35. Lee RA, Dommasch E, Treat J et al. A prospective clinical trial of open-label etanercept for the treatment of hidradenitis suppurativa. *J Am Acad Dermatol* 2009; 60(4):565-73.
 36. Gulliver WP, Jemec GB, Baker KA. Experience with ustekinumab for the treatment of moderate to severe hidradenitis suppurativa. *J Eur Acad Dermatol Venereol* 2012; 26(7):911-4.
 37. Verdolini R, Clayton N, Smith A, et al. Metformin for the treatment of hidradenitis suppurativa: a little help along the way. *J Eur Acad Dermatol Venereol* 2013; 27(9):1101-8.
 38. Brocard A, Knol AC, Khammari A, Dréno B. Hidradenitis suppurativa and zinc: a new therapeutic approach. A pilot study. *Dermatology* 2007; 214(4):325-7.
 39. Vickers MA. Operative management of hidradenitis suppurativa of the scrotum and perineum. *J Urol* 1975; 114:414-6.
 40. Aksakal AB, Adisen E. Hidradenitis suppurativa: importance of early treatment; efficient treatment with electrosurgery. *Dermatol Surg* 2008; 34(2): 228-31.
 41. Blok JL, Spoo JR, Leeman FW, et al. Skin-Tissue-sparing Excision with Electrosurgical Peeling (STEEP): a surgical treatment option for severe hidradenitis

- suppurativa Hurley stage II/III. *J Eur Acad Dermatol Venereol* 2015; 29(2):379-82.
-
42. Mandal A, Watson J. Experience with different treatment modules in hidradenitis suppurativa: a study of 106 cases. *Surgeon* 2005; 3(1):23-6.
-
43. Van Hattem S, Spoo JR, Horváth B, et Al. Surgical treatment of sinuses by deroofing in hidradenitis suppurativa. *Dermatol Surg* 2012; 38(3):494-7.
-
44. Pagliarello C, Fabrizi G, Feliciani C, Di Nuzzo S. Cryoinsufflation for Hurley stage II hidradenitis suppurativa: a useful treatment option when systemic therapies should be avoided. *JAMA Dermatol* 2014; 150(7):765-6.
-
45. Krakowski AC, Admani S, Uebelhoer NS, et Al. Residual scarring from hidradenitis suppurativa: fractionated CO₂ laser as a novel and noninvasive approach. *Pediatrics* 2014; 133(1)e248-51.
-
46. Finley EM, Ratz JL. Treatment of hidradenitis suppurativa with carbon dioxide laser excision and second intention healing. *J Am Acad Dermatol* 1996;34:465-9.
-
47. Darymple JC, Monaghan JM. Treatment of hidradenitis suppurativa with the carbon dioxide laser. *Br J Surg* 1987; 74:420.
-
48. Lapins J, Sartorius K, Emtestam L, Scanner-assisted carbon dioxide laser surgery: a retrospective follow-up study of patients with hidradenitis suppurativa. *J Am Acad Dermatol*. 2002; 47(2):280-5.
-
49. Tierney E, Mahmoud BH, Hessel C, et Al. Randomized control trial for the treatment of hidradenitis suppurativa with a neodymium-doped yttrium aluminium garnet laser. *Dermatol Surg* 2009; 35(8):1188-1198.
-
50. Downs A. Smoothbeam laser treatment may help improve hidradenitis suppurativa but not Hailey-Hailey disease. *J Cosmet Laser Ther* 2004;6(3):163-164.
-
51. Sehgal VN, Verma P, Sawant S, et Al. Contemporary surgical treatment of hidradenitis suppurativa (HS) with a focus on the use of the diode hair laser in a case. *J Cosmetic Laser Ther* 2011; 13(4):180-190.
-
52. Wang, SS; J Chen; L Keltner; et al. New technology for deep light distribution in tissue for phototherapy. *Cancer Journal* 2002; 8(2):154-63.
-
53. Scheinfeld N. The use of photodynamic therapy to treat hidradenitis suppurativa a review and critical analysis. *Dermatol Online J* 2015 Jan 15; 21(1).
-

Management of HS: approach to wounds in pre-surgical and post-surgical phase

Surgical treatment seems to be a quite common and accepted therapeutic modality for HS, as the most common non-surgical methods seldom result in a lasting cure. Several surgical treatment methods co-exist and can be recommended (Table 1, page 14) and the type of surgery and margins are selected based on the body region and severity of the disease^[1,2].

CONVENTIONAL SURGERY

Excision or curettage of individual lesions

Vigorous exteriorisation by repeated electrocauterisation and curettage of the draining sinuses may be curative in several cases^[3]. Stage I-II cases are likely to benefit from the electrosurgical procedure^[4] (12 patients, 30 lesions; 86% cure, short follow-up). Deroofing and secondary healing is a similar concept recently published^[5]. The recurrence rate of partial excision is relatively high when compared with radical excision and more complex reconstructions (100 operations, 69.88% recurrence vs 0% in 43 operations)^[6].

Total excision of the lesions and surrounding hair-bearing skin

Most surgeons recommend complete excision of the apocrine gland-bearing area delineated by the hairy surface(s) of the affected region(s) instead of limited surgical intervention^[7]. When opting for surgical cure today, extensive removal of the affected skin and underlying tissue is a uniform requirement, while further treatment and application of various reconstructive methods varies on a wide scale^[8].

Radical excision is the treatment of choice for HS. As Rompel (2001)^[9] concluded in a study of 106 operations, the method of reconstruction has no influence on recurrence and should be chosen with respect to the size and location of the excised area (Table 2)^[4].

No reconstruction (second intention healing)

Excision of the affected skin and closure by secondary healing — without reconstruction — is an option that has been practiced for decades^[10] and followed even today^[11]; (142 patients/mixed drugs/success rate 89-72% at 1 year^[12]). Patients tend to prefer secondary healing when compared to skin grafting^[13]. The main drawback of the technique is its lengthiness due to prolonged healing.

Primary closure

Less extensive defects and certain anatomical situations allow primary closure (66% success rate 92 vs 57 patients)^[14].

Reconstruction with immediate or delayed skin grafting

Split thickness skin graft (STSG) coverage of the exposed area either immediately or in a delayed fashion, 10–14 days later, is an extensively accepted method. Most descriptions do not separate the modalities (good results^[15]; 367 operations, 138 patients, 33% recurrence^[16]).

Reconstruction with skin grafting and NPWT

Wide surgical excision and skin grafting complemented with negative pressure wound healing therapy (NPWT) results in better outcomes (11 patients, 24 operations, 79.1% success^[17]; 5 patients, 8 operations, 90% graft take short follow-up^[18]).

Thomas Wild,
Surgeon, Wound Center
Dessau-Rosslau Department
of Dermatology, Dessau
Municipal Hospital,
Germany

Reconstruction with flap plasty

The use of myocutaneous flaps for reconstruction is an option for recurrent disease and carries with it good results^[19]. Defect coverage with fasciocutaneous and musculocutaneous flaps can be carried out with an acceptable recurrence rate, therefore it is recommended as a reasonable alternative (81.25% success rate, 50 operations in 35 patients)^[20]. These interventions often require the use of a stool management system or colostomy for perineal/perianal lesions^[19]. The use of a thoracodorsal artery perforator flap^[21], 12 patients, 24 operations, 6 months follow-up) may increase upper limb movement significantly (98.7 degrees pre-operatively vs 152.7 degrees post-operatively^[21]).

According to a meta-analysis of 24 studies^[22] only one study can be categorised as grade A and six as grade B evidence. A prospective randomised controlled study^[23] compared primary closure versus closure over collagen-gentamicin sponge, and found the use of local antibiotics beneficial, resulting in faster wound healing and fewer complications (200 patients, early complication 35% vs 52%, but same /40% vs 42%/ recurrence rate at 3 months). A correlation can be made between the success of the surgical intervention and its extensiveness according to a retrospective study of 31 patients (recurrence rates: drainage 100%, limited excision 42.8%, radical excision 27%)^[24]. In perianal disease wide excision is also more successful in prevention than limited excision^[25].

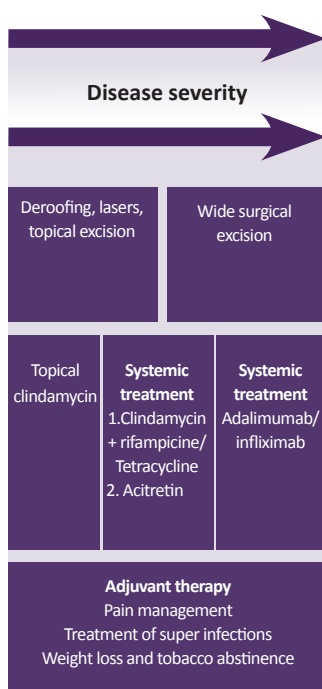
It is very difficult to compare surgical treatment modalities for HS because of the complex nature of the disease, the numerous complicated surgical interventions widely used for treatment and the variable results reported in the literature. More comparative studies are needed to move disease status from being a disease of incapacitated patients and frustrated physicians^[26].

DEROOFING

The deroofing is an effective and fast surgical technique suitable as an office procedure^[5]. This inexpensive technique converts, with limited surgery and maximal preservation of the surrounding healthy tissue, painful recurrent lesions into cosmetically acceptable scars^[5].

Due to the use of the electrosurgical loop, good haemostasis is achieved, allowing good visualisation of the operative area. The technique is especially suited for recurrent HS lesions at fixed locations in Hurley I or II areas (Box 2, page 6).

Box 1: Deroofing. Adapted^[1]



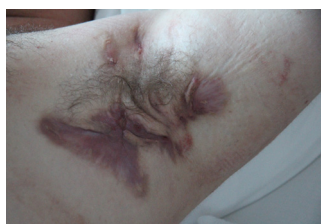For electrosurgical cutting, an Erbotom operating at 35W, with a manually controlled hand-piece fitted with a loop was used. A hyfrecator with a sharp tip, used in fulguration mode would probably give a comparable effect. The created defects were left open for healing by secondary intention.

Pre-operative assessment: Pre-operatively, HS lesions to be deroofed are identified by visual inspection and palpation, and are marked with ink. The skin is then disinfected with 0.05 mg/ml chlorohexidine solution.

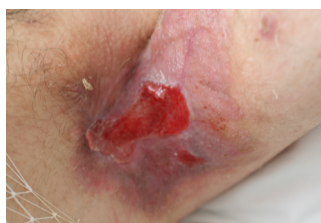Anaesthesia: Local anaesthetic solution, lidocaine 1% (10 mg/ml) plus adrenaline 1:200 (5 µg/ml) is injected in and around the lesion. Lidocaine prilocaine cream can be applied one hour before the injections.

Technique: An electrosurgical device operating at 35W, with a manually controlled hand-piece fitted with a loop can be used. A blunt probe is inserted in sinus openings. In cases where openings are not detectable make a small incision to introduce the probe. The lesion is then explored with the probe in all directions in order to find and explore all communicating tracts. Care should be taken not to create false passages with the probe. If a blunt probe is not available the blunt tip of a closed, fine forceps or 'mosquito' could also be used as a probe. Next, surgically remove the roof of the lesion using the probe as a guide. The walls are then carefully probed again for other remaining communicating sinus

Table 1: Experiences in hidradenitis suppurativa radical surgery				
	Number of treated sites	Recurrence rate	Follow-up period	References
SIH	87	31.6%	1 year	Bieniek et al ^[12]
Primary closure	92	34%	1–5 years	Van Rappard et al ^[14]
Grafts (immediate or delayed)	367	33%	1 to 19 years	Bohn and Svensson ^[16]
NPWT	24	20.9%	n.d.	Chen and Friedman ^[17]
Flaps	50	18.8%	mean 2 years	Alharbi et al ^[20]



Picture 1: Acne inversa in axilla pre-operative



Picture 2: 6 weeks post surgery (Second Intention Healing = SIH)

tracts. The gelatinous and sanguinolent material on the floor of the exposed and inflamed lesions is then scraped away with a disposable curette.

Wound healing: second intention.

Recurrence rate: 15 out of 88 (17%) deroofed lesions showed a recurrence after a median of 4.6 months (interquartile range 1.2–6.2)^[5]. Some 73 deroofed lesions (83%) did not show a recurrence after a median follow-up of 34 months (interquartile range 24–44)^[20].

Complications: post-operative bleeding, infection.

CARBON DIOXIDE (CO₂) LASER THERAPY

All surgical techniques to treat HS aim at radically removing all keratinocytes and remnants of keratinocytes in nodules, abscesses and fistulas. This can be done through excision *en bloc* of the whole or parts of an involved skin area together with the pathological process.

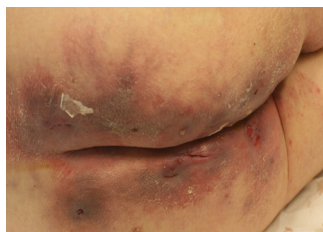Scanner-assisted CO₂ laser treatment aims at focal radical vaporisation of all nodules, abscesses and fistulas, leaving healthy tissues in between the pathological lesions. The lesions are vaporised from ‘inside and out’ until surrounding healthy tissue is reached, superficially and deep. The technique can be tissue sparing while at the same time radical.

A CO₂ laser can also be used to excise smaller or larger skin areas *en bloc* with or without laser coagulation of remnants (marsupialisation) in the deep tissues, with less bleeding and better visualisation than in standard excisions^[27,28].

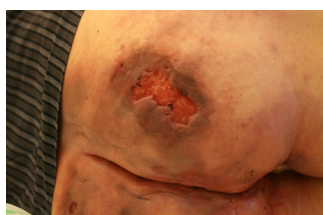The method was first described in 1987^[29] by Sherman and Reid when CO₂ laser treatment was used in 11 cases with vulvar lesions^[30]. Seven years later, Lapins et al (1994)^[31] looked at the CO₂ laser stripping-secondary intention technique. Subsequent variants of CO₂ laser HS treatment were published^[27,32]. Recently, an RCT of 61 HS patients, showed that CO₂ laser treatment was effective^[28]. In most papers, healing by secondary intention was used.

Pre-operative assessment: Symptomatic lesions are selected for treatment (i.e. those with discharge, inflammation, infiltration or suspected abscesses). Areas that had been asymptomatic for more than 2 years but showed signs of previous activity (e.g. scars with post-inflammatory, hyperpigmentation, sometimes with dry pseudocomedones) but no current inflammation are usually not treated. The diseased skin is examined macroscopically for scarring, tissue distortion and discolouration, dry or suppurating sinuses, macropseudocomedones, and other superficial signs. The examination is completed by palpating the defects for bulky indurations and small, firm subcutaneous nodules or fluctuating purulent tissue. The affected area is delineated with ink.

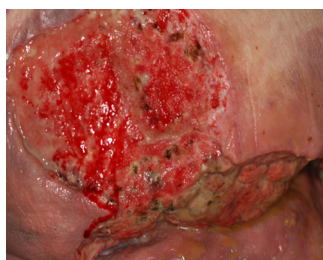Anaesthesia: After the skin is cleaned with 0.05 mg/ml chlorhexidine solution, the area is anaesthetised by injection of lidocaine (0.5 to 1.0 mg/ml) and epinephrine. To reduce pain, lidocaine prilocaine cream is applied for an hour to richly innervated areas, such as the groin,



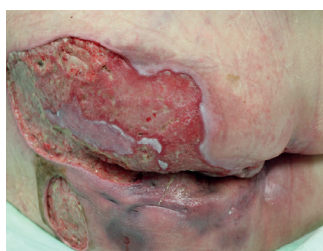Picture 3: First consultation after therapy refractory medical therapy in 2014



Picture 4: 6 weeks later with increasing wound area and inflamed tissue



Picture 5: 1 week after first unroofing



Picture 6: 4 weeks later with signs of epithelialisation

before the injections. The solution is injected and infiltrated around but not directly into the affected site to avoid direct contact with inflamed tissue and injection into the abscess.

Technique: A scanner assisted CO₂ laser was used. The laser has a focusing hand-piece attached to the miniature opto-mechanical flash scanner delivery system that generates a focal spot. This rapidly and homogeneously spiral scans and covers the area of tissue at the focal plane.

The area selected is ablated with the laser beam by passing it over the tissues with repeated ablations. Devitalised tissue is removed by cleansing the surface with a swab soaked in 0.9% sodium chloride solution. The depth of vaporisation is controlled by the selection of power, focal length, scanner-controlled spot size, and the movements of the hand-held scanner — 20W to 50W, with spot size of 3mm to 6mm, and a focal length setting of 12.5cm or 18cm, can be used. The vaporisation procedure is repeated downwards and outwards until fresh, yellow adipose tissue is exposed in the deep, relatively thin and anatomically normal skin margins laterally, with no remaining dense or discoloured tissue.

The vaporisation procedure usually reaches the deep subcutaneous fat or fascia. In the axillary and inguinal regions, major vessels and the nerve plexus must be protected, however this depth is seldom reached in Hurley Stage II lesions. The smaller blood vessels are coagulated by the laser, but bleeding from vessels larger than 0.5mm to 1mm in diameter can be stemmed with electrocoagulation or ligation.

Wound healing: The wound, left to heal by secondary intention, is immediately covered with dry or ointment-impregnated dressings, and a covering bandage attached with surgical adhesive tape or gauze underwear. The dressings are initially left on for 2 or 3 days without changing to prevent early bleeding. Thereafter, the wound is cleaned and rinsed with tap water, and the bandage is changed as often as necessary, sometimes daily, pending complete healing. A hydrofiber dressing can be used. Patients are usually able to change dressings without professional help. The wounds are inspected after 1 week and 6 weeks.

Recurrence rate: The following recurrence rates have been published following CO₂ laser treatment of HS: 2 of 185 sites^[28], 2 of 9 patients^[32], 2 of 24 patients^[28] 1 of 7 patients^[27], and 4 of 34 patients^[33]. Follow-up times vary between publications.

Complications: Complications following CO₂ laser treatment of HS are of minor importance. However, secondary infection, long healing times and scarring can occur.

Nd:YAG HAIR LASER THERAPY

Based on the assumption that HS starts in the hair follicle, the neodymium-doped yttrium aluminum garnet laser (Nd:YAG), designed for hair removal, was tried. In the first publication, 22 patients were given monthly Nd:YAG laser treatments for three months^[34]. The second publication from the same group showed the results following treatment once

Table 2: Surgical management of each individual lesion				
	Number of patients/sites	Recurrence rate	Follow-up period	References
Deroofing excision	88 lesions	17%	median 34 months	van der Zee et al ^[41]
	100 sites (PIH)	69.9%	1-7 years (median 3)	Mandall and Watson ^[6]
	87sites (SIH)	21.4%	1 year	Bieniek et al ^[42]
CO ₂ laser	185 sites	1.1%	1 to 19 years	Hazen and Hazen ^[28]
	34 patients	11.8%	34.5 months (range 15-47 months)	Lapins et al ^[33]
	24 patients	8.3%	27 months (range 15-47 months)	Lapins et al ^[33]
Electro-surgery	30 lesions	14%	mean of 16 days (range 15-21 days)	Aksakal and Adisen ^[4]

a month for 4 months^[35]. The study was randomised and contralateral body sites were used as controls. Both laser treated and control-diseased skin areas were treated with 10% benzoyl peroxide wash and 1% clindamycin gel or lotion. The scoring of lesions was blinded.

The percentage change in HS severity after 3 months of treatment was -65.3% over all anatomic sites, -73.4% inguinal, -62.0% axillary, and -53.1% inframammary. For all anatomic sites combined and each individual anatomic site, the change in HS severity from baseline to month 3 was statistically significant at the treated sites.^[34,35] The effects of the procedure appear to be maintained 2 months after the fourth laser treatment. More work is needed however before Nd:YAG lasers can be established as a standard treatment for HS (Table 2, page 15).

EXPERIMENTAL THERAPIES

IPL therapy

By reducing the number of hairs in anatomical areas prone to HS, it is assumed that recurrences would be less likely in those regions. Intense pulsed light (IPL) is one method for hair removal. In a prospective study, 18 HS patients showed a significant improvement after IPL treatment, where lesions on contralateral sites served as controls^[36]. Further studies are needed in order to establish the role of IPL treatment in HS.

PDT

Up to now, more than 20 HS patients have received photodynamic treatment (PDT), according to the literature. The first very promising publication by Gold et al (2004^[37]) was a case study of four patients who underwent 3-4 treatments of short-contact 5-aminolevulinic acid-photodynamic therapy using blue light for activation and a 3-month follow-up period^[37]. All patients had a total or almost total clinical improvement. In a similar case series of four patients who had a maximum of 4 treatments of 5-aminolevulinic acid-photodynamic therapy at weekly intervals, no significant improvement in regional HS scores was observed at follow-up visits^[38]. More recently, two open case series with PDT for HS were published. The first, with five patients, all remained unimproved^[39]. In the second, three patients out of 12 patients had complete clearance^[40]. More studies are needed to establish the role of PDT treatment in HS.

LOCAL WOUND MANAGEMENT

HS is following the pathophysiology of hyperergy wound healing. There is no evidence of different outcomes in this indication. The treatment concept should follow Fallanga’s TIME concept adapted to underlying pathophysiological processes and the advantages of bioactive substances (Table 3). Pain during dressing change should be measured by Visual Analog Scale and should not be over 4. If is over 4 pre-medication based on the WHO criteria and atraumatic dressings should be used. For larger wounds dressing changes should be undertaken in theatre.

Tissue	Necrosis	Slough	Granulation	Epithelisation
Therapy	Debridement	Alginate, Hydrofiber, NPWT	Alginate, NPWT, electrostimulation	Collagen, bismuth, electrostimulation
Infection	No	Colonisation	Infection	Multiresistant germs
Therapy	Rinsing solution for wound cleansing (0,9% NaCl, Ringer solution, PHMB-solution, Steralylth)	PVP-Iodine 5 min; PHMB 15 min; Octenidin 5 min; Steralylth 30 min; Alginat with silver, DACC	Additional: plasma, silver, bismuth, blood examination	Additional: regular screening and isolation, blood exam and culture plasma, silver, bismuth
Moisture	No	Low	Moderate	Heavy
Therapy	Draps, foams, gel dressings	Foams	Hydrofiber	Superabsorber, NPWT

REFERENCES

1. Zouboulis CC, Desai N, Emtestam L et al. European S1 guideline for the treatment of hidradenitis suppurativa/acne inversa. *J Eur Acad Dermatol Venereol* 2015; 29(4):619–44.
2. Gulliver W, Zouboulis CC, Prens E, Jemec GB, Tzellos T. Evidence-based approach to the treatment of hidradenitis suppurativa/acne inversa, based on the European guidelines for hidradenitis suppurativa. *Rev Endocr Metab Disord* 2016; [Epub ahead of print]
3. Mullins J. *Hidradenitis suppurativa*. In: Conn J, ed. *Current Therapy*. Philadelphia: WB Saunders, 1972: 592-93.
4. Aksakal AB, Adisen E. Hidradenitis suppurativa: importance of early treatment; efficient treatment with electrosurgery. *Dermatol Surg* 2008; 34:228–31.
5. van Hattem S, Spoo JR, Horvath B et al. Surgical treatment of sinuses by deroofing in hidradenitis suppurativa. *Dermatol Surg* 2012; 38:494–97.
6. Mandall A, Watson J. Experience with different treatment modules in hidradenitis suppurativa: a study of 106 cases. *Surgeon* 2005; 3:23–26.
7. Shaughnessy DM, Greminger RR, Margolis IB et al. Hidradenitis suppurativa. A plea for early operative treatment. *JAMA* 1972; 222:320–21.
8. Zouboulis CC, Bechara FG, Fritz K, Kurzen H, Liakou AI, Marsch WC, Milling A, Nast A, Podda M, Taube KM, Wienert V, Winkler T. S1 — Leitlinie zur Therapie der Hidradenitis suppurativa/ Acne inversa (ICD-10 Ziffer: L73.2). *J Dtsch Dermatol Ges* 2012;10(Suppl 5):S1-31.
9. Rompel R, Petres J. Long-term results of wide surgical excision in 106 patients with hidradenitis suppurativa. *Dermatologic surgery* 2000 Jul 1; 26(7):638–43.
10. Ariyan S, Krizek TJ. Hidradenitis suppurativa of the groin, treated by excision and spontaneous healing. *Plast Reconstr Surg* 1976; 58:44–47.
11. Banerjee AK. Surgical treatment of hidradenitis suppurativa. *Br J Surg* 1992; 79:863–66.
12. Bieniek A, Matusiak L, Chlebicka I et al. Secondary intention healing in skin surgery: our own experience and expanded indications in hidradenitis suppurativa, rhinophyma and non-melanoma skin cancers. *J Eur Acad Dermatol Venereol* 2013; 27:1015–21 (Epub 2012 Jul 23).
13. Morgan WP, Harding KG, Hughes LE. A comparison of skin grafting and healing by granulation, following axillary excision for hidradenitis suppurativa. *Ann R Coll Surg Engl* 1983; 65:235–36.
14. van Rappard DC, Mooij JE, Mekkes JR. Mild to moderate hidradenitis suppurativa treated with local excision and primary closure. *J Eur Acad Dermatol Venereol* 2012; 26:898–902.
15. Conway H, Stark RB, Climo S et al. The surgical treatment of chronic hidradenitis suppurativa. *Surg Gynecol Obstet* 1952; 95:455–64.
16. Bohn J, Svensson H. Surgical treatment of hidradenitis suppurativa. *Scand J Plast Reconstr Surg Hand Surg* 2001; 35:305–09.
17. Chen E, Friedman HI. Management of regional hidradenitis suppurativa with vacuum-assisted closure and split thickness skin grafts. *Ann Plast Surg* 2011; 67:397–401.
18. Calibre C, Bouhanna A, Salmin JP et al. Axillary hidradenitis suppurativa: A single-stage surgical treatment. *Ann Chir Plast Esthet* 2013; 58:670–75 (Epub 2011 Jul 14).
19. Gorkisch K, Boese-Landgraf J, Vaubel E. Hidradenitis suppurativa — treatment with myocutaneous island flap or the traditional method. *Handchir Mikrochir Plast Chir* 1984; 16:135–38.
20. Alharbi Z, Kauczok J, Pallua N. A review of wide surgical excision of hidradenitis suppurativa. *BMC Dermatol* 2012; 12:9.
21. Busnardo FF, Coltro PS, Olivian MV et al. The thoracodorsal artery perforator flap in the treatment of axillary hidradenitis suppurativa: effect on preservation of arm abduction. *Plast Reconstr Surg* 2011; 128:949–53.
22. Rambhatla PV, Lim HW, Hamzavi I. A systematic review of treatments for hidradenitis suppurativa. *Arch Dermatol* 2012; 148:439–46.
23. Buimer MG, Ankersmit MF, Wobbes T et al. Surgical treatment of hidradenitis suppurativa with gentamicin sulfate: a prospective randomized study. *Dermatol Surg* 2008; 34:224–27.
24. Ritz JP, Runkel N, Haier J, et al. Extent of surgery and recurrence rate of hidradenitis suppurativa. *Int J Colorectal Dis* 1998; 13:164–68.
25. Wiltz O, Schoetz DJ, Jr, Murray JJ et al. Perianal hidradenitis suppurativa. The Lahey Clinic experience. *Dis Colon Rectum* 1990; 33:731–34.
26. Mustafa EB, Ali SD, Kurtz LH. Hidradenitis suppurativa: review of the literature and management of the axillary lesion. *J Natl Med Assoc* 1980; 72:237–43.
27. Finley EM, Ratz JL. Treatment of hidradenitis suppurativa with carbon dioxide laser excision and second-intention healing. *J Am Acad Dermatol* 1996; 34:465–69.
28. Hazen PG, Hazen BP. Hidradenitis suppurativa: successful treatment using carbon dioxide laser excision and marsupialization. *Dermatol Surg* 2010; 36:208–13.
29. Dalrymple JC, Monaghan JM. Treatment of hidradenitis suppurativa with the carbon dioxide laser. *Br J Surg* 1987; 74:420.
30. Sherman AI, Reid R. CO₂ laser for suppurative hidradenitis of the vulva. *J Reprod Med* 1991; 36:113–17.
31. Lapins J, Marcusson JA, Emtestam L. Surgical treatment of chronic hidradenitis suppurativa: CO₂ laser stripping-secondary intention technique. *Br J Dermatol* 1994; 131:551–56.
32. Madan V, Hindle E, Hussain W et al. Outcomes of treatment of nine cases of recalcitrant severe hidradenitis suppurativa with carbon dioxide laser. *Br J Dermatol* 2008; 159:1309–14.
33. Lapins J, Sartorius K, Emtestam L. Scanner-assisted carbon dioxide laser surgery: a retrospective follow-up study of patients with hidradenitis suppurativa. *J Am Acad Dermatol* 2002; 47:280–85.
34. Tierney E, Mahmoud BH, Hexsel C, et al. Randomized control trial for the treatment of hidradenitis suppurativa with a neodymium-doped yttrium aluminium garnet laser. *Dermatol Surg* 2009; 35:1188–98.
35. Mahmoud BH, Tierney E, Hexsel CL, et al. Prospective controlled clinical and histopathologic study of hidradenitis suppurativa treated with the long-pulsed neodymium:yttrium-aluminium-garnet laser. *J Am Acad Dermatol* 2010; 62:637–45.
36. Highton L, Chan WY, Khwaja N, et al. Treatment of hidradenitis suppurativa with intense pulsed light: a prospective study. *Plast Reconstr Surg* 2011; 128:459–65.
37. Gold M, Bridges TM, Bradshaw VL, et al. ALA-PDT and blue light therapy for hidradenitis suppurativa. *J Drugs Dermatol* 2004; 3:S32–35.
38. Strauss RM, Pollock B, Stables GI et al. Photodynamic therapy using aminolaevulinic acid does not lead to clinical improvement in hidradenitis suppurativa. *Br J Dermatol* 2005; 152:803–04.
39. Sotiriou E, Apalla Z, Maliamani F et al. Treatment of recalcitrant hidradenitis suppurativa with photodynamic therapy: report of five cases. *Clin Exp Dermatol* 2009; 34:e235–36.
40. Schweiger ES, Riddle CC, Aires DJ. Treatment of hidradenitis suppurativa by photodynamic therapy with aminolevulinic acid: preliminary results. *J Drugs Dermatol* 2011; 10:381–386.
41. van der Zee HH, Prens EP, Boer J. Deroofing: a tissue-saving surgical technique for the treatment of mild to moderate hidradenitis suppurativa lesions. *J Am Acad Dermatol* 2010; 63:475–80.
42. Bieniek A, Matusiak L, Okulewicz-Gojlik D et al. Surgical treatment of hidradenitis suppurativa: experiences and recommendations. *Dermatol Surg* 2010; 36:1998–2004.

Addressing the impact of HS on quality of life and daily activities

Hidradenitis suppurativa (HS) is a chronic debilitating disease with no pathognomonic diagnostic test, which may contribute to diagnostic and therapeutic delay, and subsequent physical and psychological sequelae^[1]. Prevalence varies from 0.003% to 4% depending on the study population; this variance attests to a significant selection bias or misclassification^[1,2].

There is an under recognition and delay in diagnosis of HS globally^[2]. In a study involving 29 medical centres around the world, the average delay in a patient seeing a physician from onset of symptoms to the first visit is 2.3 +5 years with a diagnostic delay of 7.2 years^[2]. The delay could be the result of the patient putting off seeking medical advice or a physician taking time to make a definite diagnosis. Both point to a need for education and awareness among both patients and healthcare professionals.

Even following diagnosis of HS, many uncertainties remain, such as the course of the disease, the number of flares and expectation for a life free of symptoms. All these uncertainties associated with the disease significantly impair the patient's quality of life. HS usually begins in puberty and immediate intervention is warranted in order to decrease psychological sequelae.

ASSESSMENT TOOLS FOR DETERMINING IMPACT ON QUALITY OF LIFE

There are a number of measures, including number of lesions or dermatomes, used as decision-making parameters in dermatology. Frameworks for determining the impact of HS and other dermatological conditions on quality of life have been in development since the early 1990s. There are currently three generations of health-related quality of life (HRQoL) instruments in use:

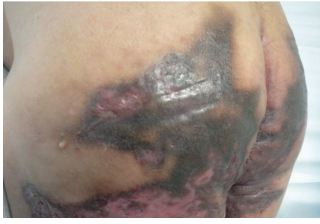- The first generation of HRQoL instruments was developed by Finlay and Khan in 1994^[3]. The Dermatology Life Quality Index (DLQI) was the first dermatology-specific, health-related quality of life questionnaire and provides a simple practical measure for routine clinical use
- The second generation of HRQoL instruments was developed from 1996 based on the psychometric knowledge available at the time. These frameworks were developed by psychologists and patients using statistics and classical test theory methods^[4], e.g. Skindex-29
- The third generation of HRQoL instruments as developed based on detailed information about dimensionality, response categories and different item functioning. Although there is not a specific third generation instrument in use in dermatology, disease-specific questionnaires developed based on this model are in use^[5].

Dermatology Life Quality Index (DLQI)

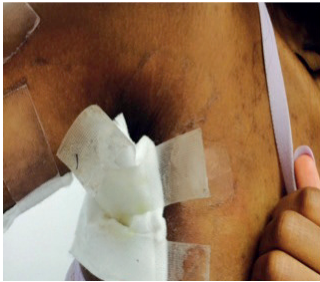Since its development in 1994, DLQI has been used in many studies to assess the burden of HS and to help several medical decision processes^[3]. DLQI has become a popular decision-making tool in determining treatment indications, reimbursement criteria and outcome measures in clinical trials.

DLQI captures some specific information that is missed by generic HRQoL instruments such as SF-36. However, it is hampered by its own limitations and has several measurement problems^[6]. It comprises 10 questions on symptoms, feelings, daily

Afsaneh Alavi,
MD, Assistant Professor of
Medicine (Dermatology),
University of Toronto,
Ontario, Canada



Picture 1: Painful inflammatory lesions in an active working male patient



Picture 2: A teenager with HS who is living in dressings

activities, leisure, work and school, personal relationships and treatment. Every question can be scored 0 to 3 and overall measures of 0 to 1 no effect, 2 to 5 a small effect, 6 to 10 a moderate effect, 11 to 20 a very large effect and 21 to 30 reflect a major impact^[7]. DLQI is reliable, valid and easy to use but it is not a good tool for diseases with high psychological impact such as HS. DLQI is also hampered by item bias, in that half of the questions are affected by factors such as age, gender, diagnosis and nationality. This can prevent effective comparison of a disease such as HS across factors including age and gender^[5].

Skindex-29

Skindex-29 is a multi-scale index for which sub-scores are reported for symptoms, emotions and functioning through 29 questions. An additional question reports the side effects of the treatment. Each question is awarded a score between 0 to 100^[8] — and each domain has multiple items^[9]. The cut-off score for severe impact in 3 domains is 52 for symptoms, 39 for emotions and 37 for functioning. A total score of more than 44 shows that the condition is having a severe impact of quality of life^[9].

QUALITY OF LIFE OF PATIENTS WITH HS

HS commonly has a profound impact on quality of life of patients resulting from pain, which renders many unable to perform everyday tasks, e.g. going to work, enjoying sport. This can be compounded by feelings of embarrassment owing to the malodorous inflammation. However, despite this the medical research community has neglected the disease and it ranks just third in the list of research priorities in the coming years^[10,11].

It is vital that HS is seen as a debilitating disease and it is important to resist the tendency to underestimate its impact on daily life, self-esteem and social interaction. The impact of HS on patients is reported comparable with other serious skin diseases, most studies used DLQI with the range of 8 to 13^[10-12].

In addition to the clinical assessment of HS, quality of life measurement and related tools provide valuable information particularly for policymakers and payers in planning for and allocating resource. In healthcare systems more weight is often given to physical rather than psychological conditions when starting systemic therapy, this is particularly true of dermatological diseases, where physicians frequently underestimate the overall impact of the disease on the lives of patients^[13].

In HS, clinical severity is not always connected to quality of life impairment, and varies on a case-by-case basis most often influenced by the location or chronicity of the disease. For example, the functional impairment for a patient with HS in one location, i.e. the genitalia would be considered mild when compared to a patient with HS in the axilla. To minimise the conflicts between disease severity and the actual disability experienced, the physical and psychological effects of HS must be considered together.

Psychosocial factors

Some patients encounter psychosocial difficulties as a result of the physical symptoms of HS. Studies have demonstrated that a physical symptom, such as pain, is the most influential factor in impairment of DLQI^[14]. A study from the Wound Care Centre, Women's College Hospital Toronto, demonstrated pain as the most distressing factor for patients with HS^[12].

The ongoing daily stress of coping with HS makes patients feel self-conscious, helpless, embarrassed, angry and frustrated about the condition. Patients with disease suffer from higher rates of anxiety, depression and sexual dysfunction.

Merely being diagnosed with HS may cause significant psychological sequelae^[15-18]. Vinding et al (2014)^[19] in a population-based study compared patients with HS with the general population; HS patients experience less work productivity and more days lost off work^[19].

Prevalence of depression in people with HS has been reported at up to 39% of patients^[10]. The severity of depression, as expected, correlates with severity of the disease. In a study by Kurek et al (2013)^[16] the severity of depression has been linked to the level of inflammatory markers such as C-Reactive Protein (CRP)^[16]. Different measures have been used to capture depression in patients with HS, including the Beck Depression Inventory and major depression inventory.

In studies, pain, discomfort, itch and embarrassment have also been important factors diminishing DLQI^[12]. In studies using Skindex-29 scores in the physical domain, pain and skin irritation had highest scores, while in the functional domain fatigue had the highest score^[10].

SOCIAL IMPACT

Patients with HS routinely experience stigmatisation and social rejection, according to direct patient feedback. Patients suffer from lack of confidence, feel embarrassed and can feel socially isolated. When combined, social isolation and rejection can result in deprivation^[20].

HS rarely affects areas of the body that are visible day-to-day, however its presence in intimate areas can have a significant impact on personal relationships in particular sexual relationships^[17]. HS most commonly affects young people during puberty exacerbating difficulties this group may already be having related to personal relationships, socialisation and social network.

Kurek et al^[17], in a study based in Berlin, compared 44 HS patients with matched control participants, and found that both female and male patients experienced significantly higher sexual dysfunction and sexual distress than the age-, sex- and BMI-matched control subjects. Furthermore, it was found that women report greater sexual distress than men with HS of similar severity^[12,17].

HS has been demonstrated to have a deleterious effect on quality of life, including employment, interpersonal relationships and mental health. Although the affected body regions are often intimate, the effect of HS on sexual health, which is an integral part of an adult's quality of life, is inadequately examined. As HS can lead to eruptions, malodorous discharge and scarring in genital areas, it may be likely that patients will experience impediments in their sexual life.

Gaining a better understanding of sexual dysfunction within this patient population is important, as a number of other studies have revealed the detrimental impact of the disease on sexual function and its subsequent effect on mental health and quality of life. For example, sexual esteem, body esteem and sexual satisfaction were found to be strong predictors of self-esteem and depression among people with physical disability^[21].

Sexual dysfunction has also been associated with heightened anger and clinical depression in men, and anxiety and depression in women^[21].

Patients with HS have also been shown to suffer higher levels of mental health difficulties, in particular depressive symptomatology, even when compared to other skin diseases such as eczema, psoriasis and cutaneous tumours. Matusiak and colleagues (2010) in their investigation of depression in HS patients found that the severity of the condition was associated with higher ratings for depression, and suggested that one-in-five patients in the study met criteria for clinical depression^[22,23].

Given the chronic nature of this condition, better understanding of its effect on sexual quality of life, and the consequences of sexual dysfunction on psychological wellbeing in patients suffering from HS is needed.

ECONOMIC IMPACT

The cost of the impact of psoriasis in US has been estimated to be \$35.2bn a year, and HS appears to be even more expensive per patient^[13]. A recent study compared the three-year cost for an HS cohort compared to psoriasis as a control group and found that double the number of patients with HS were hospitalised. The proportion of patients with HS who used the Emergency Department over the three-year period was also substantially higher than those with psoriasis (27% versus 17%)^[13].

In addition, patients with HS have comorbidities, such as obesity, which reduces their base health level when compared to the general population. The development of a health-related quality of life or disease-specific quality of life framework is necessary in order to make better decisions when developing individual patient treatment options or even determining the value of new therapies.

It is important for healthcare professionals to recognise the substantial impact that HS has on patients' quality of life. Although physical measures are an indication of psychosocial impairment experienced by the patient, optimal therapy can only be achieved by taking the patient perception of illness into account. Mild disease in certain patients needs to be aggressively treated if the impact on quality of life of the disease is to be significant.

LIVING IN DRESSINGS AND BANDAGES**Supported care**

Living with a chronic wound is challenging. There is an unmet need within the HS population in relation to wound dressings and local wound care. HS wounds vary both in terms of severity and extent. They are often located in awkward places, such as groin and axilla, and have different forms such as interconnected sinuses. Current wound care products do not meet the needs of those with with condition; therefore there is a need for research into products designed to meet the specific needs of this patient group.

Before deciding on a wound care management strategy, it is important to take an inventory of the body surface area affected, location and the morphology of skin. In addition, most patients are very reluctant to expose their entire skin surface at each visit. Often the care team needs to negotiate a skin examination.

Through (perceived) necessity, patients with HS have grown accustomed to adapting and combining dressings to cover wounds by cutting and modifying existing materials (Figure 2). Similar issues arise related to length of time for dressing changes, based on number of wounds, size and the number of dressings required.

Heavily adherent dressings can damage the fragile skin around the wound. Some patients use petrolatum based creams to prevent damaging the wound edge and periwound skin. In addition, if the dressing is ineffective in controlling exudate, patients become anxious about leakage. High levels of exudate and malodour result in more frequent dressing changes that are both time consuming and painful.

Some patients become fixated about dressings in particular when they need to be applied in hard-to-reach places. Getting dressings to conform to body contours and body movements is also problematic. A variety of products are used to keep the dressing in place such as bandages, tapes and elastic hosiery. Dressings significantly affect quality of life and time to achieve personal goals.

Wound healing post-HS surgery has been studied both in primary or secondary care. Hydrofiber^[24], alginate and silicone foam dressings^[25] have all been used with success^[26]. Post-surgical wounds in HS are very similar to pilonidal sinus or other surgeries in folds such as axilla and groin. To date no study has shown the optimal approach in wound healing in HS.

Early recognition of the high-risk patients with HS is imperative to minimise short and long-term sequelae. Often a multidisciplinary approach (primary care physician, nurses, dermatologist, surgeon and other relevant specialists) is needed to support patients' needs.

CONCLUSION

HS is a chronic debilitating inflammatory disease that physically, emotionally and psychologically impacts the patient's life. There is no single framework in place to capture the impact of all aspects of the disease. It is a disease that historically has been under diagnosed. It is embarrassing and hidden from public view, which often contributes to the delay in diagnosis. Healthcare professionals assessing and treating patients with HS can benefit from multidisciplinary team approach to optimise patient management and outcomes.

REFERENCES

- Zouboulis CC, Desai N, Emtestam L et al. European S1 guideline for the treatment of hidradenitis suppurativa/acne inversa. *J Eur Acad Dermatol Venereol* 2015; 29(4), 619-44.
- Saunte DM, Boer J, Stratigos A, Szepletowski JC, Hamzavi I, Kim KH et al. Diagnostic delay in hidradenitis suppurativa is a global problem. *Br J Dermatol* 2015; 173:1546-9.
- Finlay AY, Khan GK. Dermatology Life Quality Index (DLQI) — a simple practical measure for routine clinical use. *Clinical and experimental dermatology* 1994; 19:210-6.
- Chren MM. The Skindex instruments to measure the effects of skin disease on quality of life. *Dermatologic clinics* 2012 Apr 30; 30(2):231-6.
- Nijsten T. Dermatology life quality index: time to move forward. *The Journal of investigative dermatology* 2012; 132:11-3.
- Twiss J, Meads DM, Preston EP, Crawford SR, McKenna SP. Can we rely on the Dermatology Life Quality Index as a measure of the impact of psoriasis or atopic dermatitis? *The Journal of investigative dermatology* 2012; 132:76-84.
- Basra MK, Fenech R, Gatt RM, Salek MS, Finlay AY. The Dermatology Life Quality Index 1994-2007: a comprehensive review of validation data and clinical results. *Br J Dermatol* 2008; 159:997-1035.
- Chren MM, Lasek RJ, Quinn LM, Mostow EN, Zyzanski SJ. Skindex, a quality-of-life measure for patients with skin disease: reliability, validity, and responsiveness. *The Journal of investigative dermatology* 1996; 107:707-13.
- Prinsen CA, Lindeboom R, Sprangers MA, Legierse CM, de Korte J. Health-related quality of life assessment in dermatology: interpretation of Skindex-29 scores using patient-based anchors. *The Journal of investigative dermatology* 2010; 130:1318-22.
- Deckers IE, Kimball AB. The Handicap of Hidradenitis Suppurativa. *Dermatol Clin* 2016; 34:17-22.
- Ingram JR, Abbott R, Ghazavi M, Alexandroff AB, McPhee M, Burton T et al. The Hidradenitis Suppurativa Priority Setting Partnership. *Br J Dermatol* 2014; 171:1422-7.
- Alavi A, Anooshirvani N, Kim WB, Coultis P, Sibbald RG. Quality-of-life impairment in patients with hidradenitis suppurativa: a Canadian study. *Am J Clin Dermatol* 2015; 16:61-5.
- Kirby JS, Miller JJ, Adams DR, Leslie D. Health care utilization patterns and costs for patients with hidradenitis suppurativa. *JAMA dermatology* 2014; 150:937-44.
- Wolkenstein P, Loundou A, Barrau K, Auquier P, Revuz J, Quality of Life Group of the French Society of D. Quality of life impairment in hidradenitis suppurativa: a study of 61 cases. *J Am Acad Dermatol* 2007; 56:621-3.
- Horvath B, Janse IC, Sibbald GR. Pain management in patients with hidradenitis suppurativa. *J Am Acad Dermatol* 2015; 73:S47-51.
- Kurek A, Peters J, Milena E, Sabat R, Sterry W, Schneider-Burrus S. Depression is a frequent comorbidity in patients with acne inversa. *JDDG: Journal der Deutschen Dermatologischen Gesellschaft* 2013 Aug 1; 11(8):743-9.
- Kurek A, Peters EM, Chanwangpong A, Sabat R, Sterry W, Schneider-Burrus S. Profound disturbances of sexual health in patients with acne inversa. *J Am Acad Dermatol* 2012; 67:422-8, 8 e1.
- Sabat R, Chanwangpong A, Schneider-Burrus S, Metternich D, Kokolakis G, Kurek A et al. Increased prevalence of metabolic syndrome in patients with acne inversa. *PLoS one* 2012; 7:e31810.
- Vinding GR, Knudsen KM, Ellervik C, Olesen AB, Jemec GB. Self-reported skin morbidities and health-related quality of life: a population-based nested case-control study. *Dermatology* 2014; 228:261-8.
- Dufour DN, Emtestam L, Jemec GB. Hidradenitis suppurativa: a common and burdensome, yet under-recognised, inflammatory skin disease. *Postgrad Med J* 2014; 90:216-21; quiz 20.
- von der Werth JM, Jemec GB. Morbidity in patients with hidradenitis suppurativa. *Br J Dermatol* 2001; 144:809-13.
- Matusiak L, Bieniek A, Szepletowski JC. Psychophysical aspects of hidradenitis suppurativa. *Acta Derm Venereol* 2010; 90:264-8.
- Matusiak L, Bieniek A, Szepletowski JC. Hidradenitis suppurativa markedly decreases quality of life and professional activity. *J Am Acad Dermatol* 2010; 62:706-8, 8 e1.
- Lapins J, Marcusson JA, Emtestam L. Surgical treatment of chronic hidradenitis suppurativa: CO₂ laser stripping-secondary intention technique. *Br J Dermatol* 1994; 131:551-6.
- Morgan WP, Harding KG, Hughes LE. A comparison of skin grafting and healing by granulation, following axillary excision for hidradenitis suppurativa. *Annals of the Royal College of Surgeons of England* 1983; 65:235-6.
- Dini V, Oranges T, Rotella L, Romanelli M. Hidradenitis Suppurativa and Wound Management. *The international journal of lower extremity wounds* 2015; 14:236-44.



A Wounds International publication
www.woundsinternational.com